

Epidemiology, staging and diagnosis

EPIDEMIOLOGY AND AETIOLOGY:

Bladder cancer (BC) is the 7th most commonly diagnosed cancer in males. The worldwide age-standardised incidence rate (per 100,000 person/years) is 9.5 in men and 2.4 in women. Bladder cancer incidence and mortality rates vary across countries.

Approximately 75% of patients with BC are non-muscle-invasive bladder carcinomas (NMIBC): disease confined to the urothelium (stage Ta), carcinoma in situ or lamina propria (stage T1).

Active and passive tobacco smoking is the main risk factor, accounting for approximately 50% of cases. Occupational exposure to aromatic amines, polycyclic aromatic hydrocarbons and chlorinated hydrocarbons is the second most important risk factor for BC, accounting for about 10% of all cases. The increased risk of developing bladder cancer in patients undergoing external-beam radiotherapy, brachytherapy, or a combination, must be considered during patient follow-up.

PATHOLOGICAL STAGING AND CLASSIFICATION SYSTEMS:

2017 TNM CLASSIFICATION OF URINARY BLADDER CANCER

| T - Primary Tumour | |
|--------------------------|---|
| Tx | Primary tumour cannot be assessed |
| T0 | No evidence of primary tumour |
| Ta | Non-invasive papillary carcinoma |
| Tis | Carcinoma <i>in situ</i> : "flat tumour" |
| T1 | Tumour invades subepithelial connective tissue |
| T2 | Tumour invades muscle |
| T2a | Tumour invades superficial muscle (inner half) |
| T2b | Tumour invades deep muscle (outer half) |
| T3 | Tumour invades perivesical tissue: |
| T3a | microscopically |
| T3b | macroscopically (extravesical mass) |
| T4 | Tumour invades any of the following: prostate stroma, seminal vesicles, uterus, vagina, pelvic wall, abdominal wall |
| T4a | Tumour invades prostate stroma, seminal vesicles, uterus, or vagina |
| T4b | Tumour invades pelvic wall or abdominal wall |
| N - Regional Lymph Nodes | |
| Nx | Regional lymph nodes cannot be assessed |
| N0 | No regional lymph node metastasis |
| N1 | Metastasis in a single lymph node in the true pelvis (hypogastric, obturator, external iliac, or presacral) |
| N2 | Metastasis in multiple regional lymph nodes in the true pelvis (hypogastric, obturator, external iliac, or presacral) |
| N3 | Metastasis in a common iliac lymph node(s) |
| M - Distant Metastasis | |
| M0 | No distant metastasis |
| M1a | Non-regional lymph nodes |
| M1b | Other distant metastasis |

- **T1 subclassification:** the depth and extent of invasion into the lamina propria has been demonstrated to be of prognostic value and its use is recommended by the most recent 2016 World Health Organization (WHO) classification.

- **Carcinoma in situ (CIS) and its classification:** CIS is a flat, HG, non-invasive urothelial carcinoma. It is often multifocal and can be missed or misinterpreted as an inflammatory lesion during cystoscopy.

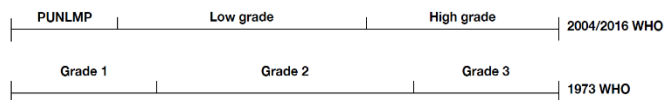
From a clinical point of view, CIS may be classified as:

- **Primary:** CIS with no previous or concurrent papillary tumours and no previous CIS.
- **Secondary:** CIS during follow-up of patients with a previous not-CIS tumour.
- **Concurrent:** CIS in the presence of any other urothelial tumour in the bladder.

- **Histological grading of NMIBC:** NMIBC is classified according to the WHO 1973 (G1-G3) and/or the WHO 2004/2016 (PUNLMP, LG/HG) systems.

Both systems are prognostic for progression, but not for recurrence.

WHO 2004/2016 provides better reproducibility than the 1973 classification.



DIAGNOSIS: - Patient history and physical examination: A focused patient history and urological examination are mandatory.

- **Signs and symptoms:** Haematuria is the most common finding in NMIBC. CIS might be suspected in patients with lower urinary tract symptoms.

| | | |
|-------------------|--|--------|
| - Imaging: | Use renal and bladder ultrasound and/or computed tomography-intravenous urography (CT-IVU) during the initial work-up in patients with haematuria. | Strong |
| | Once a bladder tumour has been detected, perform a CT urography in selected cases (e.g., tumours located in the trigone, multiple or high-risk tumours). | Strong |

- **Urinary molecular marker tests:** Sensitivity is usually higher at the cost of lower specificity compared to urine cytology. Promising novel urinary biomarkers, assessing multiple targets, have been tested in prospective multicentre studies.

- **Urinary cytology:** high sensitivity in HG and G3 tumours (84%), but low sensitivity in LG/G1 tumours (16%). Cytology is useful, particularly as an adjunct to cystoscopy, in patients with HG/G3 tumours.

- **Cystoscopy:** Describe all macroscopic features of the tumour (site, size, number, and appearance) and mucosal abnormalities during cystoscopy. Use a bladder diagram.

- **Transurethral resection of TaT1 bladder tumours:** Transurethral resection of the bladder tumour (TURB) followed by pathology investigation of the obtained specimen(s) is an essential step in the management of NMIBC. TURB Transurethral should be performed systematically in individual steps.

| | |
|--|--------|
| Use voided urine cytology as an adjunct to cystoscopy to detect high-grade tumour. | Strong |
| Perform cytology on at least 25 mL fresh urine or urine with adequate fixation. Morning urine is not suitable because of the frequent presence of cytolysis. | Strong |
| Use the Paris System for cytology reporting. | Strong |
| Perform cystoscopy in patients with symptoms suggestive of bladder cancer or during surveillance. It cannot be replaced by cytology or by any other non-invasive test. | Strong |
| In men, use a flexible cystoscope, if available and apply irrigation 'bag squeeze' to decrease procedural pain when passing the proximal urethra. | Strong |
| Perform <i>en-bloc</i> resection or resection in fractions (exophytic part of the tumour, the underlying bladder wall and the edges of the resection area). | Strong |
| Avoid cauterisation as much as possible during TURB to avoid tissue deterioration. | Strong |
| In patients with positive cytology, but negative cystoscopy, exclude an upper tract urothelial carcinoma, CIS in the bladder (by mapping biopsies or PDD-guided biopsies) and tumour in the prostatic urethra (by prostatic urethra biopsy). | Strong |
| Perform a second TURB in the following situations: <ul style="list-style-type: none"> • after incomplete initial TURB, or in case of doubt about completeness of a TURB; • if there is no detrusor muscle in the specimen after initial resection, with the exception of Ta LG/G1 tumours and primary CIS; • in T1 tumours. | Strong |
| If indicated, perform a second TURB within 2–6 weeks after the initial resection. This second TURB should include resection of the primary tumour site. | Weak |
| Register the pathology results of a second TURB as it reflects the quality of the initial resection. | Weak |
| Inform the pathologist of prior treatments (intravesical therapy, radiotherapy, etc.). | Strong |
| The pathological report should specify tumour location, tumour grade and stage, lymphovascular invasion, subtypes of urothelial carcinoma (variant histologies), presence of CIS and detrusor muscle. | Strong |

| | |
|---|--------|
| Take biopsies from abnormal-looking urothelium. Biopsies from normal-looking mucosa (mapping biopsies from the trigone, bladder dome, right, left, anterior and posterior bladder wall) are recommended if cytology or urinary molecular marker test is positive. If the equipment is available, perform fluorescence-guided (PDD) biopsies. | Strong |
| Take a biopsy of the prostatic urethra in cases of bladder neck tumour, if bladder carcinoma <i>in situ</i> is present or suspected, if there is positive cytology or urinary molecular marker test without evidence of tumour in the bladder, or if abnormalities of the prostatic urethra are visible. If biopsy is not performed during the initial procedure, it should be completed at the time of the second resection. | Strong |
| Take a prostatic urethral biopsy from the pre-collicular area (between the 5 and 7 o'clock position) using a resection loop. In case any abnormal-looking areas in the prostatic urethra are present at this time, these need to be biopsied as well. | Weak |
| Use methods to improve tumour visualisation (fluorescence cystoscopy, narrow-band imaging) during TURB, if available. | Weak |